Pregnancy and Periodontium: A Narrative Review

[1]Dr. Shahnaz, [2]Nafisa Begum, [3]Rajdeep Dhara, [4]Dibyadyuti Jana, [5]Md Wasim Ahmad Ansari, [6]Ariba Wasim, [7]Arkaprabha Koley

[1-7]Dentistry and Oral Sciences

[1-7]Kusum Devi Sunderlal Dugar Jain Dental College &Hospital, Kolkata, India

***Abstract*—This project investigates the bidirectional relationship between pregnancy and periodontal health. During gestation, elevated hormone levels—specifically estrogen and progesterone—exaggerate the gingival response to plaque, leading to pregnancy gingivitis [3,5]. Conversely, maternal periodontitis may be a risk factor for preterm birth and low birth weight due to the spread of oral pathogens and inflammatory mediators to the feto-placental unit [2,4]. However, evidence regarding the efficacy of periodontal therapy in reducing these risks remains mixed [1,9,10], maintaining periodontal health is essential for prenatal care.**

***Index Terms*—pregnancy, periodontitis, gingivitis, hormonal changes, preterm birth, periodontal therapy**

I. Introduction

Pregnancy induces profound physiological adaptations that significantly impact the oral cavity **[6]** to systemic health. This relationship is driven by two primary dynamics:Hormonal Modulation: How pregnancy hormones exacerbate gingival inflammation **[5]**.Systemic Impact: How periodontal infection may serve as a reservoir for pathogens that threaten the developing fetus **[2,4]**.

II. Epidemiology

Gingival alterations are highly prevalent during pregnancy:

Gingivitis: Affects 30% to 100% of pregnant women [**3**].

Periodontitis: Approximately 40% of pregnant women suffer from some form of periodontal disease [**2**].

III. Hormonal Influence on Periodontal Tissues

The primary driver of gingival changes during pregnancy is the hormonal surge [**5**].

Estrogen and Progesterone: Estrogen levels increase over 100-fold, and progesterone levels rise significantly [**5,6**].

Vascular Changes: These hormones induce vasodilation (widening of blood vessels), leading to the characteristic erythema (redness) and increased bleeding tendency **[5]**.

Cellular Metabolism: Gingival tissues metabolize progesterone, which can suppress the local immune response and allow acute inflammation to become chronic **[5].**

Prostaglandins: Hormones stimulate the gingival production of Prostaglandin E2, a potent mediator of inflammation **[5].**

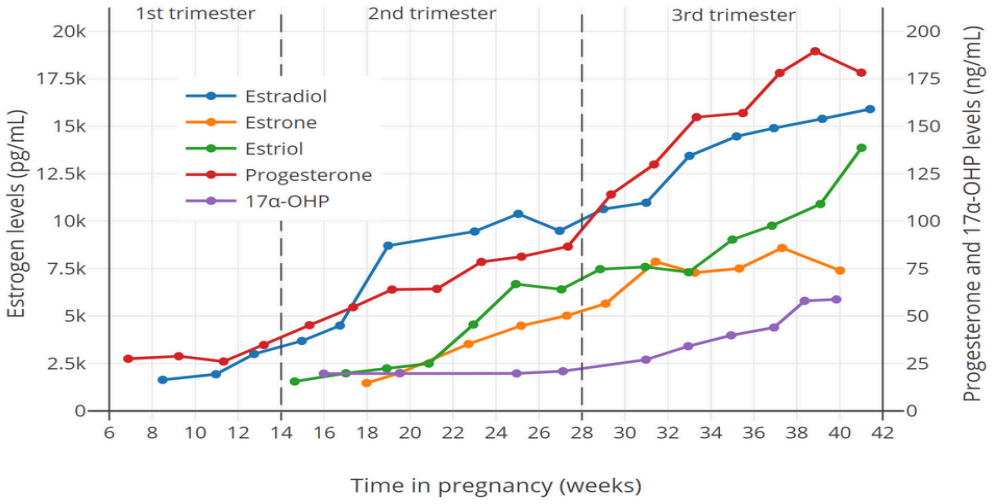

Figure 1: Hormonal fluctuations throughout the trimesters of pregnancy.[12]

IV. Microbiological Changes

The hormonal environment of pregnancy fosters the growth of specific anaerobic bacteria **[7].**Hormonal Nutrition: Prevotella intermedia utilizes progesterone and estradiol as essential growth factors (substituting for Vitamin K), leading to a marked increase in its population during the second trimester **[7,8].**



Figure 2: Prevotella intermedia, a bacterium that thrives on pregnancy hormones.[13]

V. Clinical Features

Appearance: Gingiva appears dark red, edematous (swollen) and smooth **[3].**

Bleeding: Increased bleeding on probing is a hallmark sign **[3].**

Progression: Signs typically appear in the second month and peak around the eighth month **[3].**

Mobility: Increased horizontal mobility may occur due to hydration of the periodontal ligament rather than destruction of bone **[3].**



Figure 3a. Gingival-Enlargement-2-Months-after-Pregnancy-Left-Lateral-View. [14]



Figure 3b.Gingival-Enlargement-2-Months-after-Pregnancy-Right-Lateral-View. [15]



Figure 3c. Gingival-Enlargement-2-Months-after-Pregnancy-Frontal-View.[16]

VI. Pregnancy-Associated Periodontal Conditions

A. Pregnancy Gingivitis

This is a non-specific, vascularizing inflammation. It is an aggravated response to dental plaque caused by the altered hormonal milieu **[3,5]**.

B. Pyogenic Granuloma (Pregnancy Tumor)

Description: A benign, painless, pedunculated mass typically found on the interdental papilla **[5].**

Etiology: An exaggerated inflammatory response to local irritation modified by hormones **[5]**.

Management: Lesions usually regress postpartum. Surgical excision during pregnancy is reserved for cases involving severe bleeding or functional interference **[2,5]**.



Figure 4: A Pyogenic Granuloma (Pregnancy Tumor) on the gingiva.[17]

VII. Periodontitis and Adverse Pregnancy Outcomes

Epidemiological studies suggest maternal periodontitis is a risk factor for:

Preterm Birth (PTB): Delivery before 37 weeks **[2,4]**.

Low Birth Weight (LBW): Ep Birth weight less than 2,500g **[2,4]**.

Preeclampsia: Hypertension and proteinuria during pregnancy **[2]**.

VIII. Pathogenic Mechanisms

Two primary pathways link periodontal infection to adverse pregnancy outcomes **[2,4]**:

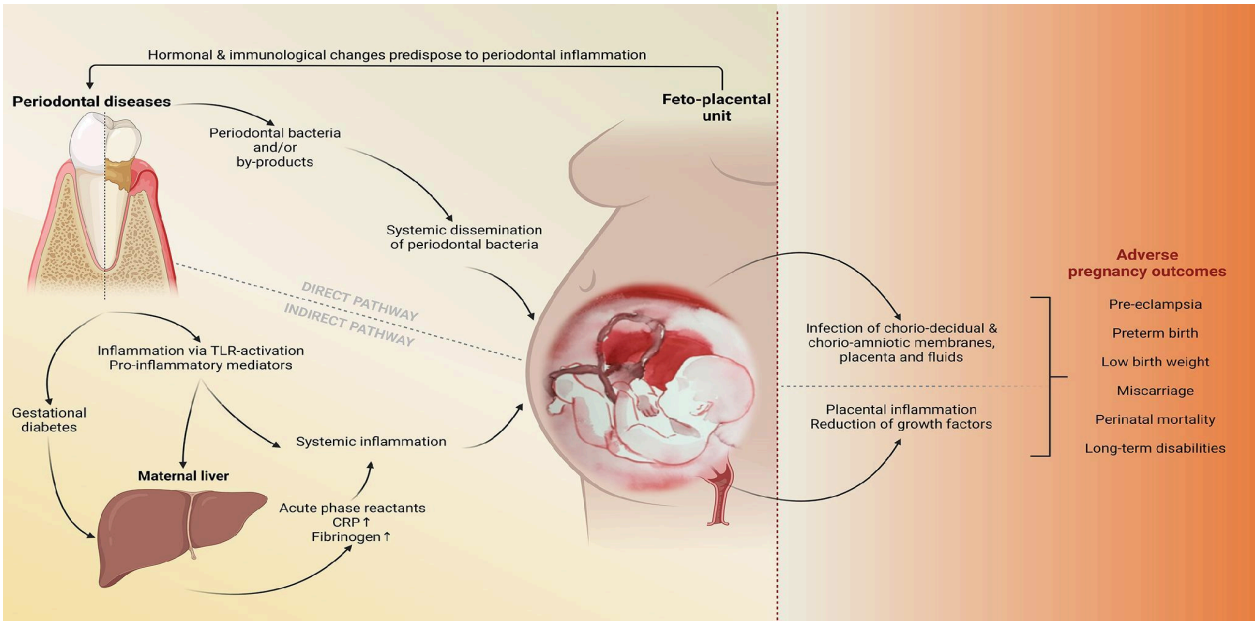

Figure 5: Pathways linking oral infection to fetal complications.[18]

A. Direct Pathway (Hematogenous Spread)

Oral bacteria (e.g., F. nucleatum) translocate into the maternal bloodstream, cross the placental barrier, and colonize the amniotic fluid. F. nucleatum has been recovered from the cord blood of preterm infants **[2,4]**.

B. Indirect Pathway (Inflammatory Mediators)

Periodontal inflammation releases cytokines (IL-1 beta, IL-6, TNF-alpha) and prostaglandins (PGE2) into systemic circulation. These mediators can reach the uterus and trigger the production of prostaglandins that stimulate uterine contractions and cervical ripening, mimicking the initiation of labor **[2,4].**

IX. Periodontal Management

Timing of Treatment

First Trimester: Focus on plaque control and oral hygiene instruction. Avoid elective procedures during organogenesis **[2]**.

Second Trimester (14-27 weeks): The safest window for non-surgical therapy (Scaling and Root Planing) **[2]**.

Third Trimester: Focus on comfort and hygiene; lengthy appointments may cause supine hypotensive syndrome **[2]**.

Therapeutic Modalities

Scaling and Root Planing (SRP): Safe and effective for reducing bacterial load **[11]**.

Adjuncts: Chlorhexidine rinses. Systemic antibiotics should be used cautiously **[2]**.

Nutrition: Supplementation with Vitamin D and Calcium may benefit periodontal and fetal health **[2]**.

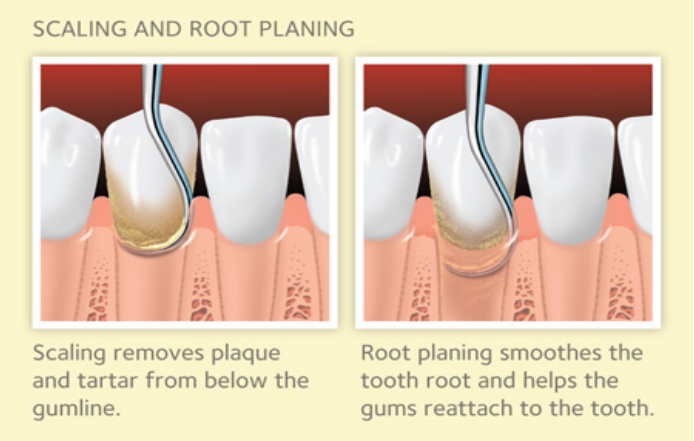

Figure 6: Scaling and root planing procedure to remove subgingival calculus.[19]

X. Conclusion

Pregnancy represents a significant physiological stress test for the periodontium. While current evidence regarding the ability of periodontal treatment to prevent adverse birth outcomes is conflicting **[9,10,11]**, maintaining periodontal health remains a critical component of holistic prenatal care. Interdisciplinary collaboration is essential to ensure the well-being of both mother and child.

References

[1] Srinivas SK, Parry S. Periodontal Disease and Pregnancy Outcomes: Time to Move On? Journal of Women's Health. 2012;21(2).

[2] Nannan M, Xiaoping L, Ying J. Periodontal disease in pregnancy and adverse pregnancy outcomes: Progress in related mechanisms and management strategies. Frontiers in Medicine. 2022.

[3] Laine MA. Effect of pregnancy on periodontal and dental health. Acta Odontologica Scandinavica. 2002;60:257-264.

[4] Zi MYH, Longo PL, Bueno-Silva B, Mayer MPA. Mechanisms involved in the association between periodontitis and complications in pregnancy. Frontiers in Public Health. 2015.

[5] Mealey BL, Moritz AJ. Hormonal influences: effects of estrogen and progesterone. Periodontology 2000. 2003.

[6] Fox SI. Human Physiology. 1993.

[7] Kornman KS, Loesche WJ. The subgingival microbial flora during pregnancy. Journal of Periodontal Research. 1980.

[8] Kornman KS, Loesche WJ. Effects of estradiol and progesterone on Bacteroides melaninogenicus and Bacteroides gingivalis. Infection and Immunity. 1982.

[9] Macones GA, Parry S, Nelson DB, et al. Treatment of localized periodontal disease in pregnancy does not reduce the occurrence of preterm birth: results from the Periodontal Infections and Prematurity Study (PIPS). American Journal of Obstetrics & Gynecology. 2010.

[10] Offenbacher S, Beck JD, Jared HL, et al. Effects of periodontal therapy on rate of preterm delivery: a randomized controlled trial (MOTOR Study). Obstetrics & Gynecology. 2009;114:551-559.

[11] Michalowicz BS, Hodges JS, DiAngelis AJ, et al. Treatment of periodontal disease and the risk of preterm birth. New England Journal of Medicine. 2006;355:1885-1894.

[12] Medgirl131, "Estrogen and progesterone levels during pregnancy in women," Wikimedia Commons, Jan. 8, 2020.

[13] T. Yamanaka et al., "Scanning electron micrographs showing surface structures of Prevotella intermedia strains," ResearchGate, Aug. 25, 2011.

[14] S. Arora et al., "Gingival Enlargement 2 Months after Pregnancy (Left Lateral View)," ResearchGate, Nov. 2016.

[15] S. Arora et al., "Gingival Enlargement 2 Months after Pregnancy (Right Lateral View)," ResearchGate, Nov. 2016

[16] S. Arora et al., "Gingival Enlargement 2 Months after Pregnancy (Frontal View)," ResearchGate, Nov. 2016.

[17] F. Ahmed, "Tumors," Dentist For You.

[18] N. Bostanci, “Periodontal Health and Pregnancy Outcomes: Time to Deliver,” Acta Obstetricia et Gynecologica Scandinavica, vol. 102, no. 6, pp. 648–651, May 2023, doi: 10.1111/aogs.14548.

[19] American Dental Association, "Scaling and Root Planing for Gum Disease," MouthHealthy.